



ELSEVIER

## Distal biceps tendon tears in women

Christopher R. Jockel, MD<sup>a,b</sup>, Phillip J. Mulieri, MD, PhD<sup>a,c</sup>, Mark R. Belsky, MD<sup>b</sup>,  
Bruce M. Leslie, MD<sup>b,\*</sup>

<sup>a</sup>Department of Orthopaedic Surgery, Tufts Medical Center, Boston, MA, USA

<sup>b</sup>Department of Orthopaedic Surgery, Newton-Wellesley Hospital, Newton, MA, USA

<sup>c</sup>Citrus Orthopaedic and Joint Institute, Lecanto, FL, USA

**Hypothesis:** Is the presentation and outcome of surgical treatment of distal biceps tendon tears different in women than men?

**Materials and methods:** From 1999 to 2008, 15 cases of distal biceps tendon tears in 13 female patients were treated surgically at a single institution. Mean age was 63 years (range, 48-79 years). A retrospective review evaluated patient presentation, diagnosis, and treatment. Postoperative outcomes were assessed by physical examination, a patient satisfaction survey, the American Shoulder and Elbow Surgeons (ASES) elbow assessment form, and the Disabilities of the Arm, Shoulder, and Hand (DASH) questionnaire.

**Results:** Two-thirds of the tears were in the dominant arm, of which 7 resulted from a single injury, and 8 reported insidious onset of symptoms. All patients presented with pain in the antecubital fossa. A distinct cystic mass was palpable in 6. Of the 15 cases, 13 were partially detached, 1 was completely detached, and 1 was weakly attached. Fourteen regained full strength, and all had nearly complete range of motion. Mean follow-up was 46 months (range, 2-117 months). Eleven completed a postoperative patient satisfaction survey, ASES elbow, and DASH questionnaire. Mean scores were 95 (range, 58-100) for ASES and 7 (range, 0-43) for DASH. The only complication was a transient lateral antebrachial cutaneous nerve sensory palsy.

**Discussion:** Distal biceps tendon tears in women present at an advanced age with no history of an acute injury. They are frequently associated with a cystic mass and have a predominance of partial tears.

**Conclusions:** Distal biceps tendon tears in women present differently than in men. The tears are rarely complete and they respond well to surgical repair.

**Level of evidence:** Level IV, Case Series, Treatment Study.

© 2010 Journal of Shoulder and Elbow Surgery Board of Trustees.

**Keywords:** Distal biceps tendon; complete tear; partial tear; female

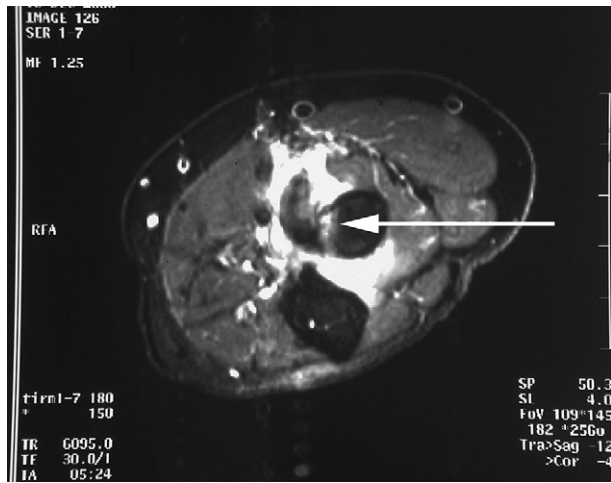
Although distal biceps tendon tears are being reported with increasing frequency, these injuries remain relatively rare, representing 3% of all biceps tendon tears and having an incidence of 1.2/100,000 patients.<sup>9,33</sup> Tear of the distal biceps typically occurs in the dominant arm of men aged 40

to 60 years, after a single traumatic event, which is usually a sudden eccentric load. Patients with a complete tendon tear generally present with acute pain, swelling, weakness in flexion and supination, and a palpable defect in the antecubital fossa. Anatomic surgical repair of the biceps to the radial tuberosity is generally recommended for optimal recovery.<sup>2,25,31</sup>

Compared with men, reports of distal biceps tendon tears in women are extremely rare. Although some isolated

\*Reprint requests: Bruce M. Leslie, MD, 2000 Washington St, Suite 343, Newton, MA 02462.

E-mail address: [bml Leslie@aol.com](mailto:bml Leslie@aol.com) (B.M. Leslie).



**Figure 1** A short-tau inversion recovery axial magnetic resonance image in a 72-year-old woman with a 3-month history of atraumatic anterior elbow pain and a palpable cystic mass demonstrates a partial distal biceps tendon tear with peritendinous edema at the level of the radial tuberosity. The *arrow* shows the tendon detached from the radial tuberosity.

cases have been reported, most distal biceps tears in women are scattered throughout orthopedic and radiology studies addressing other management issues.<sup>3,4,5,10,11,14,23,29,33,35-37</sup> To our knowledge, no large series of complete or partial distal biceps tendon tears in women has been reported, and these injuries remain poorly characterized. Our purpose is to present a series of partial and complete distal biceps tendon tears in women and to review the presentation, treatment, and outcomes.

## Materials and methods

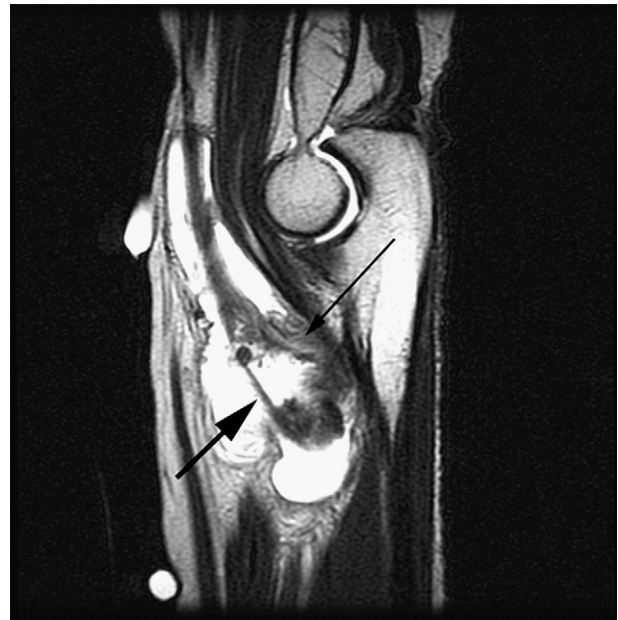This study was approved by the Newton Wellesley Hospital Institutional Review Board (IRB #N09-452).

## Patients

From 1999 to 2008, 15 cases of distal biceps tendon tears in 13 female patients were treated surgically at a single institution by 2 board-certified orthopedic surgeons. Dr Leslie treated 10 cases and Dr Belsky treated 5. The patients were culled from the surgeons' personal operative databases, and the patients' presentations, diagnoses, and treatments were documented in a retrospective review.

The patients were a mean age of 63 years (range, 48-79 years). The dominant arm was involved in 10 cases and the non-dominant arm in 5. Two patients had bilateral tears treated at separate times. Four patients were retired, and only 1 performed heavy manual labor as part of her job. Three patients reported a specific work-related injury with documented workers' compensation.

All patients presented with pain in the antecubital fossa, having had symptoms for a mean duration of 9.4 months (range 0.5-96 months) before evaluation. Seven cases could be traced to a single injury, and 8 reported the insidious onset of symptoms. Six patients noted swelling in the antecubital fossa, and 5 of these patients had a distinct palpable cystic mass on physical examination. One patient



**Figure 2** A 58-year-old office manager presented with a 4-month history of insidious antecubital fossa pain. She had swelling and a palpable cystic mass on examination. A T2 sagittal magnetic resonance image demonstrated a high-grade partial distal biceps tendon tear (*thin black arrow*) with only a few fibers still attached to the radial tuberosity (*large arrow*). The tendon is surrounded by fluid.

had a distinct cystic mass on physical examination that was not associated with subjective swelling. No patients reported bruising or ecchymosis. There was variable discomfort to resisted supination in 9, resisted flexion in 7, and palpation of the biceps tendon in 8. The tendon appeared intact in all but 1 case. All patients presented with full range of motion except for a patient who lacked 10° of flexion and 45° of extension relative to the contralateral side. Five of 15 had mild weakness in both flexion and supination with manual testing, and 10 had full strength not limited by pain.

Plain radiographs were taken in all but 2 cases. Three patients had focal heterotopic calcifications at the radial tuberosity. One patient had a computed tomography scan as part of a tumor workup for an antecubital fossa mass that revealed no bony abnormality. All patients underwent magnetic resonance imaging studies that were interpreted as showing 14 partial tears of the distal biceps tendon and 1 complete tear. Peritendinous fluid or a cystic ganglion in the antecubital fossa was identified in every patient (*Fig. 1* and *Fig. 2*).

Conservative treatment, including splinting, rest, activity modification, and anti-inflammatory medications was initially attempted for all patients. No patient had corticosteroid injections or physical therapy. Operative repair was performed only after a course of nonoperative management had failed. The usual indication for surgery was persistent pain, although 1 patient with a cystic mass was mistakenly thought to have a tumor.

## Operative repair

A single 6- to 10-cm curvilinear anterior incision distal to the antecubital fossa was used to expose the biceps tendon with a modified Henry approach.<sup>22</sup> The lateral antebrachial cutaneous

**Table I** Patient demographics

Case	Age (y)	Arm	Occupation	Mechanism of injury	Time to presentation* (mon)	Tear grade	Antecubital fossa mass	Other
1	74	D	Retired	Trimming shrubs	5	H	Yes	Bilateral
2	79	ND	Retired	Insidious	1.5	H	No	Bilateral
3	72	ND	Deli Worker	Carrying food	7	H	Yes	
4	68	ND	Retired	Insidious	3	L	No	
5	58	D	Visiting Nurse	Lifting backpack	1.5	C	No	WC
6	55	D	Mechanical assembler	Cutting metal	8	H	No	WC
7	72	D	Retired	Insidious	3	H	Yes	
8	48	D	Chef	Lifting bucket	1	H	No	WC
9	66	ND	Dental assistant	Insidious	4	H	Yes	
10	71	D	Desk Clerk	Insidious	1	C	Yes	
11	52	D	City Planner	Pilates workout	2	H	No	
12	56	D	Tax Preparer	Painting	96	H	No	
13	58	D	Manager	Insidious	4	H	Yes	Bilateral
14	52	D	Marketing	Insidious	4	L	No	
15	59	ND	Manager	Insidious	0.5	H	No	Bilateral

C, Complete; D, dominant; H, high-grade partial; L, low-grade partial; ND, nondominant; WC, workers compensation.

\* Represents time from symptom onset to diagnosis.

nerve was identified and gently retracted. The lacertus fibrosus, when intact, was released to facilitate exposure. The biceps tendon was identified and followed down towards its insertion on the radial tuberosity with the arm supinated at all times. Partial tears of the tendon were divided into complete, high-grade partial (>50%), and low-grade partial (≤50%) tears based on operative reports quantifying the percentage of tendon tear. Once exposed, any intact biceps tendon fibers were sharply released from the radial tuberosity to complete the tear.

The distal tendon was conservatively débrided of degenerative tissue and a Bunnell-type or Krakow-type whip stitch was placed using nonabsorbable #5 Ethibond (Ethicon Inc, Somerville, NJ) or #2 Fiberwire (Arthrex Inc, Naples, FL). The radial tuberosity was débrided of residual bursal and tendinous tissue, and a unicortical opening large enough to contain the end of the distal tendon was created at the biceps insertion. In 10 cases, sutures were passed straight posteriorly through drill holes made in the posterior cortex, avoiding the posterior interosseous nerve.

A second small posterior incision was made to retrieve the suture ends and advance the biceps into the trough in the radial tuberosity. The sutures were tied over the posterior muscles, making no attempt to dissect down to the underlying bony cortex.<sup>22</sup> In the other 5 cases, the small posterior incision was not used. In 4 of these 5, fixation was through drill holes on the side of the radial cortex away from the posterior interosseous nerve, and in 1 patient, tendon fixation was with an Endobutton (Acufex, Smith and Nephew, Andover, MA) technique.<sup>1</sup>

After closure, the arm was placed in a well padded posterior long-arm splint with the arm flexed 90° and the forearm in neutral rotation to limit tension on the repair. At the first postoperative visit about 1 week later, the splint was removed and changed to a long-arm cast in a similar position. The arm was immobilized for a total of 4 weeks and was then placed in a hinged brace with extension stop at the degree of flexion noted at the 1-month visit. The extension stop was gradually decreased until full extension was reached. Strengthening exercises were begun at 8 weeks and

resisted exercises at 3 months. Return to all activities was allowed at 12 to 16 weeks after surgery.

Patients were seen for postoperative follow-up and evaluated at final examination for manual strength testing, range of motion, and postoperative complications. Long-term follow-up was also available for 9 patients with 11 distal biceps repairs. One patient died, and 3 could not be contacted. Those who returned for long-term follow-up had a repeat clinical assessment and completed the American Shoulder and Elbow Surgeons (ASES) elbow assessment form and the Disabilities of the Arm, Shoulder, and Hand (DASH) questionnaire. Patient satisfaction was rated on a visual analog scale of 0 to 10, with 0 being not satisfied and 10 being completely satisfied with surgery. Patients were also asked if they would have the surgery again and whether they would recommend the surgery to a family member or friend with a similar problem.

## Results

Tables I and II present the results of patient demographics and surgical treatment outcomes. Mean nonoperative treatment duration was 3.3 months (range, 0.5-8 months), with operative repair performed in all patients after a mean symptomatic period of 12.7 months (range, 2.5 months-8.4 years).

Operative reports demonstrated 1 complete full-thickness tear and 1 nearly complete tear. The nearly complete tear was firmly attached to the tuberosity by scar tissue that could be detached by blunt dissection. The complete tear was less firmly attached to the tuberosity by scar tissue and was tethered by the lacertus fibrosus. The partial tears consisted of 11 high-grade and 2 low-grade tears. Thirteen of 15 arms had a significant peritendinous fluid collection within the tenosynovial sheath of the torn distal biceps tendon. None of the torn tendons were retracted proximally.

**Table II** Results of surgical repair

Case	Follow-up (mon)	Flex/extend (°)	Supinate/pronate (°)	Strength*		Post-op patient assessment		
				Flexion	Supinate	ASES	DASH	Satisfaction†
1	117	130/0	85/80	5	5	97	6	10
2	60	135/0	85/80	5	5	97	6	10
3	111	130/0	80/75	5	5	100	0	10
4	16	140/0	90/80	5	5	58	43	10
5	9	135/0	80/80	5	5			
6	14	140/0	85/85	5	5			
7	96	140/0	85/80	5	5	100	0	10
8	7	130/10	80/80	5	5			
9	14	140/0	85/80	5	5	100	0	10
10	108	140/0	90/80	5	5	100	3	10
11	96	145/0	90/85	5	5	100	0	10
12	6	145/0	80/70	5	5			
13	13	150/−5	85/85	5	5	98	5	10
14	15	135/0	90/80	5	5	99	5	10
15	2	150/0	85/75	4	4	100	5	10

ASES, American Shoulder and Elbow Surgeons elbow assessment; DASH, Disabilities of the Arm, Shoulder, and Hand.

\* Strength testing on scale of 1 to 5: 5, full; 4, noticeably weak; 3, antigravity; 2, contraction only; 1, none.

† Patient satisfaction based on visual analog scale (range, 0-10), with 0 being not satisfied and 10 being completely satisfied.

All patients returned for postoperative evaluation. The 15 arms had painless full range of motion, and 14 regained full 5/5 motor strength in flexion and supination. The mean follow-up time was 46 months (range, 2-117 months). The postoperative patient satisfaction survey, the ASES elbow score, and DASH questionnaires were completed for 11 of 15 arms. The mean ASES elbow score was 95 (range 58-100) and the mean DASH score was 7 (range 0-43). These patients all reported 10/10 satisfaction after surgical repair, would recommend surgery, and would have surgery again for a similar problem. Only 1 patient had suboptimal DASH and ASES elbow scores but reported complete satisfaction with the surgical repair. Her arm functional deficits were based on poor hand function due to Dupuytren's disease and were not related to any complaints about the elbow. One lateral antebrachial cutaneous nerve sensory paresthesia resolved by 14.5 months.

One patient (No. 13 & 15) who had bilateral injury, did not return for in-office follow-up after 2 months from her second surgery. She reported transportation difficulty and was comfortable managing her own rehabilitation because she had experience with rehabilitation of the contralateral arm. She completed the ASES elbow assessment for the second arm by telephone at 5.5 months. Although not confirmed in the office, she reported full strength in the arm at that time.

Of the 11 patients who worked, 5 were able to return to full-duty work without modification, 2 returned to modified duty, and 3 did not return to work. It was unclear from the records if 1 patient was able to return to work. One of the 3 workers' compensation patients returned to work on modified duty, and 2 did not return to work. No patients from the workers' compensation group returned for evaluation

with the ASES elbow assessment form, DASH questionnaire, or patient satisfaction survey.

## Discussion

In contrast to their well-described male counterparts, limited data are available regarding the presentation and treatment of women with distal biceps tendon tears. To our knowledge, this is the first report evaluating the presentation, treatment, and outcomes of a series of female patients treated operatively for partial and complete distal biceps tendon tears. A review of the literature identified reports on 21 distal biceps tendon tears in female patients; however, clinical data were available for only 5 partial and 7 complete tears.<sup>3-5,10,11,14,23,29,33,35-37</sup> In this study, we reviewed 15 cases of distal biceps tendons that were either partially or completely torn in 13 women treated with operative repair. Overall, patients had excellent clinical outcomes and were very satisfied.

The diagnosis of distal biceps tendon tears in women is challenging and requires a high index of clinical suspicion. Unlike men, who typically present with an acute traumatic injury, the women in this study often presented with the insidious onset of symptoms. Unlike men, who typically sustain complete tendon tears, most women present with a partial tendon injury. Prior reports have confirmed the difficulty of identifying partial tears, which may have contributed to the extended duration of symptoms before orthopedic referral.<sup>18,19,31,36</sup> The most common clinical presentation was pain in the antecubital fossa, with variable discomfort to resisted supination, resisted flexion, and

palpation of the distal biceps tendon. In situations where the diagnosis remains unclear, magnetic resonance imaging is useful to confirm partial and complete distal biceps tendon tears.<sup>11-13,37</sup>

There are multiple reports of distal biceps tendon tears presenting with a cystic mass in the antecubital fossa. Falchhook et al<sup>11</sup> described 3 patients with an antecubital fossa mass after complete tendon tear, while Durr et al<sup>10</sup> reported 3 of 4 partial tears with a bursa-like lesion. In the Durr report, 1 patient was referred for evaluation of a suspected tumor, whereas in the former, 2 patients were evaluated for suspected neoplasm. In another report, a female patient presented with a partial distal biceps tear and an antecubital fossa mass causing median nerve compression in the forearm.<sup>14</sup> In our study, 6 of 15 arms had a distinct palpable cystic mass, 2 of which were referred for a tumor work-up. Considering these findings, tear of the distal biceps tendon should be considered in the differential diagnosis of a female patient with an antecubital fossa mass and a relevant clinical presentation.<sup>4,23</sup>

Prior studies suggest a potential age discrepancy between men and women presenting with distal biceps tendon tears. The mean age for women in previous reports is 65 years for partial and 63 years for complete tears.<sup>3,5,10,14,23,29,33,35</sup> These findings are similar to the mean age of 63 years in our study. Compared with women, men with distal biceps tear typically present slightly younger, with an average age reported of approximately 50 years at the time of tear.<sup>31</sup> This discrepancy in age is important to consider when counseling patients, because different treatment recommendations may be appropriate for each patient based on the anticipated functional demands and the surgical risks.

Surgical reattachment of the biceps tendon to the radial tuberosity is generally recommended as a safe and effective treatment for torn distal biceps. Multiple studies have shown the benefits of anatomic repair for both partial and complete tendon injury. Studies by Baker et al<sup>2</sup> and Morrey et al<sup>25</sup> revealed improved flexion and supination strength with surgical reattachment of complete tears. Other reports have shown decreased pain, improved strength, and patient satisfaction with repair of partial tears.<sup>8,19,32,36</sup> Kelly et al<sup>19</sup> assessed subjective patient outcomes after operative repair of partial distal biceps tendon tears in men using the ASES elbow assessment form. The mean ASES elbow score was 96, with all patients having nearly complete strength and range of motion. In our report, the mean ASES elbow score was 95 and the mean DASH score was 7. The only complication was a transient lateral antebrachial cutaneous nerve palsy. Given these findings, we agree with prior reports that surgical repair is a safe and effective treatment for distal biceps tears in both men and women.<sup>8,29,36</sup>

Unlike their male counterparts, all the women in this series successfully underwent primary repair. None of these partial or complete distal biceps tendon tears required a graft. This was most likely because the distal biceps tears in these women were generally partial tears and were therefore still tethered to the radial tuberosity. In the patient with a complete

distal biceps tendon tear, the tendon was weakly attached to the radial tuberosity by scar tissue and was still tethered by the lacertus fibrosis.

Multiple theories have been proposed regarding the etiology of distal biceps tendon tears. Current theories include a degenerative process, mechanical impingement, and a hypovascular zone of the tendon.<sup>7,34</sup> Aging has been shown to diminish the structural properties of a tendon, with increased cross-linking of collagen, a relative decrease in elastin content, and a reduction in glycosaminoglycan concentration<sup>17,24</sup> that lead to a decrease in resistance to tensile load and may predispose to tear.<sup>27,35</sup> The advanced age of presentation, insidious onset of symptoms, and high incidence of partial tears suggests distal biceps tendon tears in women may be due to a predominantly degenerative etiology.

The reasons for the gender disparity in the frequency of distal biceps tendon tears remain unclear. The predominance of tears in men may be related to their increased muscular cross-sectional area that generates a greater force across the biceps tendon.<sup>35</sup> Similar gender differences have also been observed with respect to Achilles, patellar, and quadriceps tendon tears. The incidence of male/female Achilles tendon tear is reportedly between 3:1 and 6:1, quadriceps tendon tear between 4:1 and 8:1, and patellar tendon tear approximately 3.5:1.<sup>6,15,16,21,28,30</sup> Nyssonen et al<sup>26</sup> has suggested that the male predominance of Achilles injuries may be due to different levels of sporting activities between the sexes.<sup>26</sup>

This study has several limitations. Given that all patients were identified through surgical reports, we did not identify patients who might have responded well to conservative therapy. With prior reports of satisfactory outcomes after both operative and nonoperative treatment in women, it is difficult to speculate about how many and which patients will improve with conservative measures and which may only recover with surgery.<sup>10,35</sup> Because patients were identified in a retrospective manner, preoperative DASH and ASES scores were not available. Similarly, no formal preoperative or postoperative biomechanical strength testing was done. Prior reports have confirmed, however, the associated functional and biomechanical gains achieved with surgical reattachment of the biceps tendon.<sup>8,20,25,36</sup>

## Conclusions

This study reviewed the presentation, treatment, and outcomes of partial and complete distal biceps tendon tears in women treated with surgical repair. These patients presented at an advanced age, often with no history of acute injury, and had experienced pain in the antecubital fossa for an extended duration. Frequently, these patients also present with an associated cystic mass. Women with partial and complete

distal biceps tendon tears had a predominance of partial tears that responded well to anatomic surgical reattachment.

## Disclaimer

The authors, their immediate families, and any research foundations with which they are affiliated have not received any financial payments or other benefits from any commercial entity related to the subject of this article.

## References

- Bain GI, Prem H, Heptinstall RJ, Verhellen R, Paix D. Repair of distal biceps tendon rupture: a new technique using the Endobutton. *J Shoulder Elbow Surg* 2000;9:120-6 (doi:10.1016/S1058-274690040-5).
- Baker BE, Bierwagen D. Rupture of the distal biceps brachii: operative versus non-operative treatment. *J Bone Joint Surg Am* 1985;67:414-7 (PMID: 3972865).
- Bauman JT, Sotereanos DG, Weiser RW. Complete rupture of the distal biceps tendon in a woman: case report. *J Hand Surg [Am]* 2006; 31:798-800 (PMID: 16713845).
- Belli P, Costantini M, Mirk P, Leone A, Pastore G, Iviarano P. Sonographic diagnosis of distal biceps tendon rupture: a prospective study of 25 cases. *J Ultrasound Med* 2001;20:587-95 (PMID: 11400932).
- Bourne MH, Morrey BF. Partial rupture of the distal biceps tendon. *Clin Orthop Relat Res* 1991;271:143-8 (PMID: 1914289).
- Clayton RA, Court-Brown CM. The epidemiology of musculoskeletal tendinous and ligamentous injuries. *Injury* 2008;39:1338-44, doi:10.1016/j.injury.2008.06.021. PMID: 19036362.
- Davis WM, Yassine Z. An etiological factor in tear of the distal tendon of the biceps brachii: report of 2 cases. *J Bone Joint Surg Am* 1956;38: 1365-8 (PMID: 13376661).
- Dellaero DT, Mallon WJ. Surgical treatment of partial biceps tendon ruptures at the elbow. *J Shoulder Elbow Surg* 2006;15:215-7, doi:10.1016/j.jse.2005.08.020. PMID: 16517368.
- Dobbie RP. Avulsion of the lower biceps brachii tendon: analysis of fifty-one previously reported cases. *Am J Surg* 1941;51:662-83 (doi: 10.1016/S0002-961090203-9).
- Durr HR, Stabler A, Pfahler M, Matzko M, Refior HJ. Partial rupture of the distal biceps tendon. *Clin Orthop Relat Res* 2000;374:195-200 (doi:10.1097/00003086-200005000-00018).
- Falchook FS, Zlatkin MB, Erbacher GE, Moulton JS, Bisset GS, Murphy BJ. Rupture of the distal biceps tendon: evaluation with MR imaging. *Radiology* 1994;190:659-63 (PMID: 8115606).
- Festa A, Mulieri P, Newman J, Spitz D, Leslie BM. Effectiveness of magnetic resonance imaging in detecting partial and complete distal biceps tendon rupture. *J Hand Surg [Am]* 2010;35:77-83, doi:10.1016/j.jhsa.2009.08.016.
- Fitzgerald SW, Curry DR, Erickson SJ, Quinn SF, Friedman H. Distal biceps tendon injury: MR imaging diagnosis. *Radiology* 1994;191: 203-6 (PMID: 8134571).
- Foxworthy M, Kininmonth WG. Median nerve compression in the proximal forearm as a complication of partial rupture of the distal biceps brachii tendon. *J Hand Surg [Br]* 1992;17:515-7 (doi:10.1016/S0266-768180234-7).
- Houshian S, Tscherning T, Riegels-Nielsen P. The epidemiology of Achilles rupture in a Danish county. *Injury* 1998;29:651-4 (doi:10.1016/S0020-138300147-8).
- Józsa L, Kvist M, Bálint BJ, et al. The role of recreational sport activity in Achilles tendon rupture. *Am J Sports Med* 1989;17:338-43. doi:10.1177/036354658901700305; PMID: 2729483.
- Kannus PK, Jozsa L. Histopathological changes preceding spontaneous rupture of a tendon. *J Bone Joint Surg Am* 1991;73:1507-25 (PMID: 1748700).
- Kelly EW, Morrey BF, O'Driscoll SW. Complications of distal biceps tendon repairs. *J Bone Joint Surg Am* 2000;82:1575-81 (PMID: 11097447).
- Kelly EW, Steinmann S, O'Driscoll SW. Surgical treatment of partial distal biceps tendon ruptures through a single posterior incision. *J Shoulder Elbow Surg* 2003;12:456-61 (doi:10.1016/S1058-274600052-1).
- Leighton MD, Bush-Joseph CA, Bach BR. Distal biceps brachii repair: results in dominant and nondominant extremities. *Clin Orthop Relat Res* 1995;317:114-21 (PMID: 7671464).
- Leppilahi J, Puranen J, Orava S. Incidence of Achilles tendon rupture. *Acta Orthop Scand* 1996;67:277-9 (PMID: 8686468).
- Leslie BM, Ranger H. Reattachment of the ruptured distal biceps tendon using a modified anterior approach. *Tech Hand Up Extrem Surg* 2000;4:93-100 (doi:10.1097/00130911-200006000-00005).
- Logan PM, Janzen DL, Connell DG. Tear of the distal biceps tendon presenting as an antecubital mass: magnetic resonance imaging appearances. *Can Assoc Radiol J* 1996;47:342-6 (PMID: 8857968).
- Maffulli N, Wong J, Almedkinders LC. Types and epidemiology of tendinopathy. *Clin Sports Med* 2003;22:675-92 (doi:10.1016/S0278-591900004-8).
- Morrey BF, Askew LJ, An KN, Dobyns JH. Rupture of the distal tendon of the biceps brachii: a biomechanical study. *J Bone Joint Surg Am* 1985;67:418-21 (PMID: 3972866).
- Nyyssönen T, Lüthje P, Kröger H. The increasing incidence and difference in sex distribution of Achilles tendon rupture in Finland in 1987-1999. *Scan J Surg* 2008;97:272-5 (PMID: 18812279).
- O'Brien M. Functional anatomy and physiology of tendons. *Clin Sports Med* 1992;11:505-20 (PMID: 1638638).
- O'Shea K, Kenny P, Donovan J, Condon F, McElwain JP. Outcomes following quadriceps tendon ruptures. *Injury* 2002;33:257-60 (doi:10.1016/S0020-138300110-3).
- Peeters T, Ching-Soon NG, Jansen N, Sneyers C, Declercq G, Verstreken F. Functional outcome after repair of distal biceps tendon ruptures using the Endobutton technique. *J Shoulder Elbow Surg* 2009; 18:283-7, doi:10.1016/j.jse.2008.10.004. PMID: 19101177.
- Puranik GS, Faraj A. Outcome of quadriceps tendon repair. *Acta Orthop Belg* 2006;72:176-8 (PMID: 16768261).
- Ramsey ML. Distal biceps tendon injuries: diagnosis and management. *J Am Acad Orthop Surg* 1999;7:199-207 (PMID: 10346828).
- Rokito AS, McLaughlin JA, Gallagher MA, Zuckerman JD. Partial rupture of the distal biceps tendon. *J Shoulder Elbow Surg* 1996;5:73-5 (doi:10.1016/S1058-274680034-6).
- Safran MR, Graham SM. Distal biceps tendon ruptures: incidence, demographics, and the effect of smoking. *Clin Orthop Relat Res* 2002;404: 275-83. doi:10.1097/00003086-200211000-00042; PMID: 12439270.
- Seiler JG, Parker LM, Chamberland PD, Sherbourne GM, Carpenter WA. The distal biceps tendon. Two potential mechanisms involved in its rupture: arterial supply and mechanical impingement. *J Shoulder Elbow Surg* 1995;4:149-56 (doi:10.1016/S1058-274680044-8).
- Toczyłowski HM, Balint CR, Steiner ME, Boardman M, Scheller AD. Complete rupture of the distal biceps brachii tendon in female patients: a report of 2 cases. *J Shoulder Elbow Surg* 2002;11:516-8. doi:10.1067/mse.2002.126617; PMID: 12378174.
- Vardakas DG, Musgrave DS, Varitimidis SE, Goebel F, Sotereanos DG. Partial rupture of the distal biceps tendon. *J Shoulder Elbow Surg* 2001; 10:377-9. doi:10.1067/mse.2001.116518; PMID: 11517369.
- Williams BD, Schweitzer ME, Weishaupt D, et al. Partial tears of the distal biceps tendon: MR appearance and associated clinical findings. *Skeletal Radiol* 2006;30:560-4. doi:10.1007/s002560100397; PMID: 11685478.