

# Effectiveness of Magnetic Resonance Imaging in Detecting Partial and Complete Distal Biceps Tendon Rupture

Anthony Festa, MD, Philip J. Mulieri, MD, PhD, Joel S. Newman, MD, Damon J. Spitz, MD,  
Bruce M. Leslie, MD

**Purpose** A magnetic resonance imaging (MRI) scan of the elbow is often obtained to confirm the clinical suspicion of a distal biceps tendon rupture. The goal of this study was to evaluate the effectiveness of MRI in diagnosing partial and complete distal biceps tendon ruptures as determined at the time of surgery.

**Methods** We identified 22 partial and 24 complete distal biceps tendon ruptures operated on by a single surgeon. The preoperative MRIs of these patients were obtained, along with MRIs of the elbow in 10 asymptomatic individuals. Two musculoskeletal radiologists read each MRI without knowledge of the diagnosis or the surgical findings. Their interpretations were compared with the intraoperative findings and the results were statistically analyzed.

**Results** The overall sensitivity and specificity of MRI were 92.4% and 100%, respectively, in detecting distal biceps tendon ruptures. The sensitivity and specificity of MRI for complete tears were 100% and 82.8%, respectively. The sensitivity and specificity of MRI for partial tears were 59.1% and 100%, respectively.

**Conclusions** Magnetic resonance imaging is an effective tool for diagnosing distal biceps tendon ruptures. Although MRI is extremely sensitive in diagnosing complete tears, it is substantially less sensitive in diagnosing partial tears. (*J Hand Surg* 2010;35A:77–83. Copyright © 2010 by the American Society for Surgery of the Hand. All rights reserved.)

**Type of study/level of evidence** Diagnostic II.

**Key words** MRI, distal, biceps, tendon.

NOT ALL PATIENTS present with the classic signs and symptoms of a complete distal biceps tendon rupture.<sup>1–17</sup> Complete tears without retraction and partial tears may have a more subtle presentation than complete, retracted tears. Such tears may not present with the usual proximal muscle migra-

tion and associated ecchymosis. Patients with partial distal biceps tendon tears may present with mild thickening of the distal tendon or subtle proximal migration of the musculotendinous junction. Many times the only report is anterior elbow pain. Sometimes the symptoms may even mimic or coexist with other conditions such as bicipital tendinosis.<sup>18</sup> Sometimes the diagnosis of chronic distal biceps tendon tears can even be missed or delayed.<sup>2,19–23</sup>

When the diagnosis of distal biceps tendon rupture is suspected but uncertain, a magnetic resonance image (MRI) of the elbow is frequently obtained. Several studies have evaluated the use of MRI to diagnose partial and complete distal biceps tendon ruptures. These studies have predominantly focused on describing the characteristic MRI findings. Whereas these studies comment on the accuracy of MRI in detecting partial and complete tears, none have con-

From the Tufts University Affiliated Residency Program, Boston; the Department of Radiology, New England Baptist Hospital, Boston; and the Department of Orthopaedic Surgery, Newton Wellesley Hospital, Newton, MA.

Received for publication November 4, 2008; accepted in revised form August 26, 2009.

No benefits in any form have been received or will be received related directly or indirectly to the subject of this article.

**Corresponding author:** Bruce M. Leslie, MD, Department of Orthopaedic Surgery, Newton Wellesley Hospital, Suite 343, 2000 Washington Street, Newton, MA 02462; e-mail: [bmleslie@aol.com](mailto:bmleslie@aol.com).

0363-5023/10/35A01-0015\$36.00/0  
doi:10.1016/j.jhssa.2009.08.016

firmed all their cases surgically.<sup>24–26</sup> O’Driscoll et al compared the accuracy of MRI and surgical findings when evaluating the accuracy of a specific physical examination maneuver (the hook test).<sup>27</sup> To our knowledge, no study has been performed whose primary goal was to evaluate the sensitivity and specificity of MRI for detecting partial and complete tears of the distal biceps tendon.<sup>24–28</sup> This was the primary purpose of our study.

## MATERIALS AND METHODS

We obtained internal review board approval at the participating institution before the study commenced. A consecutive series of 46 patients who had an MRI and underwent surgical repair for partial or complete distal biceps tears between 1996 and 2006, by a single surgeon at a single hospital, was identified from the surgeon’s personal database. Elbow MRIs performed during the preoperative work-up of these patients were obtained. To be included in this study, the MRI images had to satisfy the following criteria: (1) the patient’s name and birth date, the date of study, and the extremity imaged had to be identifiable on the study; (2) an area from proximal to the biceps musculotendinous junction to past the radial tuberosity had to be viewable on the study; (3) the MRI hardware needed a magnet strength of 1.5 T; (4) no contrast was used. Because a small proportion of patients were referred with MRIs from outside institutions, a standard protocol for obtaining images could not be used. All scans included T1, T2, and a fluid/edema-sensitive sequence in the axial, sagittal, and coronal planes.

We performed a chart review to identify the time between symptom onset and MRI, and the time between MRI and surgery. For study purposes, tears were defined as acute or chronic based on the timing of MRI. Acute tears were defined as less than or equal to 4 weeks from symptom onset to MRI scan. Chronic tears were defined as greater than 4 weeks from symptom onset to MRI scan. Chart review was performed to identify pertinent patient demographics, as well as pertinent intraoperative findings.

To be included in the study, patients had to satisfy the following criteria: (1) age greater than 18 years; (2) no previously diagnosed elbow injury or condition; and (3) no previous elbow surgery.

We used surgical notes to identify the degree of distal biceps tendon tear and the presence of tendon retraction. A complete distal biceps tendon tear was defined as a complete loss of the normal attachment of the distal end of the biceps tendon to the radial tuberosity. A tendon that was weakly attached to the tuber-

osity by either scar or pseudotendon was considered a complete tear. Scar or pseudotendon could easily be divided by blunt dissection. Conversely, if any tendinous attachment to the radial tuberosity remained, the tear was defined as partial. With partial tears, the remaining fibers could not be separated by blunt dissection; the fibers needed to be sharply transected to mobilize the tendon for repair. For incomplete ruptures, we estimated the percentage of tendon rupture by determining what percentage of the distal biceps was still attached. This estimation was facilitated by transecting the remaining distal biceps tendon fibers that were still attached to the tuberosity.<sup>6,17,22</sup> For study purposes, a low-grade partial tear was defined as less than or equal to a 50% tear of the distal biceps tendon attachment. A high-grade partial tear was defined as a greater than 50% tear of the distal biceps tendon attachment. Surgical findings were considered the reference standard for identifying complete or incomplete distal biceps tendon tears in this study. We also obtained MRI images of 10 elbows of asymptomatic individuals who were recruited solely to serve as a control group.

Two fellowship-trained musculoskeletal radiologists read each MRI scan in random order without knowledge of the diagnosis. The radiologists participating in this study had no role in the original care of any patient involved in this study. The radiologists were told that the indication for MRI was suspicion of a distal biceps tendon injury, but they were unaware which films were from patients with surgically confirmed distal biceps tendon ruptures and which were from asymptomatic controls. They were asked to characterize the distal biceps tendon as intact, partially torn, or completely torn. If the radiologist suspected a partial distal biceps tendon tear, he was asked to characterize it as either a high-grade or low-grade tear using the definition provided. The radiologists were also instructed to document the presence (or absence) of (1) tendon discontinuity, (2) intratendinous signal, (3) increased peritendinous fluid, (4) increased signal in the biceps muscle, (5) increased signal in the surrounding soft tissues, and (6) edema in the radial tuberosity. The MRI interpretations were then compared with the intraoperative findings and the results were statistically analyzed (SPSS Software, Chicago, IL). Values reported for sensitivity, specificity, positive predictive value, and negative predictive value were calculated for each radiologist. The reported numbers in this study represent the mean values calculated from each radiologist’s results. The radiologists were instructed not to discuss the cases with one another.

**TABLE 1. Comparison of Radiologist #1's MRI Interpretation and Surgical Findings**

Radiologist's Interpretation	Surgical Findings			
	No Tear	Low-Grade Partial	High-Grade Partial	Complete Tear
No tear	<b>10</b>	1	2	
Low-grade partial		<b>5</b>	4	
High-grade partial			<b>3</b>	
Complete Tear			7	<b>24</b>

Bolded values represent agreement of radiologist's interpretation with surgical findings.

**TABLE 2. Comparison of Radiologist #2's MRI Interpretation and Surgical Findings**

Radiologist's Interpretation	Surgical Findings			
	No Tear	Low-Grade Partial	High-Grade Partial	Complete Tear
No tear	<b>10</b>	2	2	
Low-grade partial		<b>4</b>	6	
High-grade partial			<b>4</b>	
Complete tear			4	<b>24</b>

Bolded values represent agreement of radiologist's interpretation with surgical findings.

## RESULTS

After application of the previous criteria, a total of 56 MRIs were available for review. These included 10 asymptomatic elbows, and 22 confirmed partial and 24 confirmed complete distal biceps tendon ruptures. The mean age was 46 years (range, 29–67 y) in the asymptomatic control group, 45 years (range, 20–69 y) in the partial tear group, and 47 years (range, 35–60 y) in the complete tear group. There was no significant difference in age between the partial ( $p=.86$ ) or complete tear group ( $p=.60$ ) and the control group. The control group included 10 men, the partial tear group included 22 men, and the complete tear group included 23 men and 1 woman. The median time from onset of symptoms to MRI was 26 days (range, 8–132 d) in the partial tear group, compared with 10 days (range, 1–189 d) in the complete tear group. The median time from MRI to surgery was 37 days (range, 1–120 d) in the partial tear group, compared with 14 days (range, 1–104 d) in the complete tear group. The decision to proceed to surgery was based on a number of factors including the clinical evaluation, the MRI interpretation, and the patient's vocational and avocational schedule.

A total of 12 of 22 partial tears were characterized as acute, compared with 19 of 24 complete tears. Of the 22 partial tears, 6 were defined as low-grade based on surgical findings and 16 were defined as high-grade based on surgical findings.

Both radiologists correctly identified all 10 asymptomatic control elbows as having no tears on MRI. Of note, 1 radiologist identified 1 elbow in the control group as having mild tendinosis. Because the control group did not have surgery, this diagnosis was not confirmed. Both radiologists also correctly identified all 24 complete tears on MRI (Tables 1, 2). Review of the

surgical notes revealed that 18 of the 24 complete tears showed some degree of tendon retraction.

When comparing MRI interpretations with intraoperative findings, radiologist #1 correctly identified 5 of 6 low-grade tears and 3 of 16 high-grade tears (Table 1). Radiologist #1 misread 1 low-grade tear as having no tear but did identify some degree of tendinosis. Of the 16 surgically confirmed high-grade partial tears, 7 were incorrectly identified as having complete tears, 4 as having low-grade partial tears, and 2 as having no tears. Of the 10 partial tears that radiologist #1 read as either intact or completely torn, 7 were defined as acute, and 3 as chronic.

Radiologist #2 correctly identified 4 of 6 low-grade tears and 4 of 16 high-grade tears (Table 2). Radiologist #2 misread 2 low-grade tears as having no tear but did identify some degree of tendinosis. (One of the 2 was the same patient whom radiologist #1 had read as having no tear, but having some degree of tendinosis.) Of the 16 surgically confirmed high-grade partial tears, 4 were incorrectly identified as having complete tears, 6 as having low-grade partial tears, and 2 as having no tears. Of these 8 partial tears that radiologist #2 read as either intact or completely torn, 5 were defined as acute and 3 were defined as chronic.

Of the documented partial tears that were read on MRI as having no tears, the mean percentage of tear (the amount of tendon detached from the tuberosity defined intraoperatively) was 47%. Of the partial tears that were read on MRI as having complete tears, the mean degree of tear identified intraoperatively was 78%.

Overall in our series, MRI had a sensitivity of 92.4% and a specificity of 100% in detecting distal biceps tendon ruptures. The sensitivity and specificity in detecting partial distal biceps tendon ruptures were 59.1% and 100%, respectively. The positive predictive value

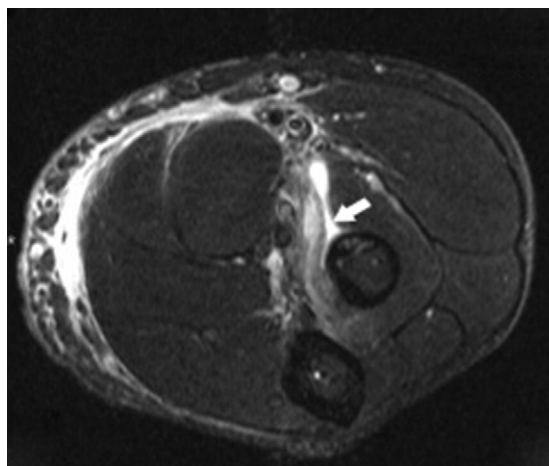
**TABLE 3. Accuracy of MRI in Detecting Distal Biceps Ruptures**

	Complete	Partial
Sensitivity	100%	59.1%
Specificity	82.8%	100%
PPV	81.4%	100%
NPV	100%	79.1%

PPV, positive predictive value; NPV, negative predictive value.

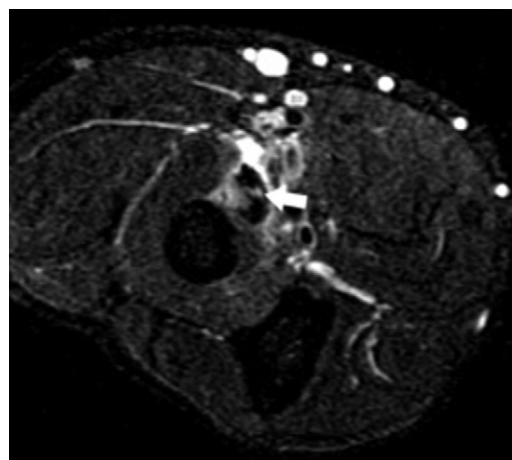
**TABLE 4. MRI Findings for Distal Biceps Ruptures**

MRI Finding	Complete	Partial
Tendon discontinuity	100%	27.2%
Increased intratendinous signal intensity	68.8%	63.7%
Peritendinous or intrasheath fluid signal	74.9%	61.4%
Increased signal intensity: biceps muscle	66.7%	6.5%
Increased signal intensity in surrounding soft tissue	75%	32%
Edema in radial tuberosity	4.2%	22.7%



**FIGURE 1:** Axial image, Short Tau Inversion Recovery sequence. Complete tear. Absence of tendon at insertion site on radial tuberosity with fluid signal in sheath (white arrow).

was 100% and the negative predictive value was 79.1%. The sensitivity and specificity in detecting complete distal biceps ruptures were 100% and 82.8%, respectively. The positive predictive value was 81.4% and the negative predictive value was 100% (Table 3). The interobserver agreement among the radiologists in this study was 80.6% for partial biceps tears and 100% for complete biceps tears. The most common MRI

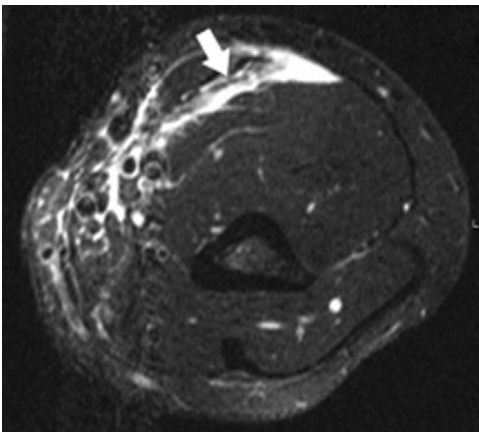


**FIGURE 2:** Axial image, Short Tau Inversion Recovery sequence. Partial tear. Increased intratendinous signal (white arrow).

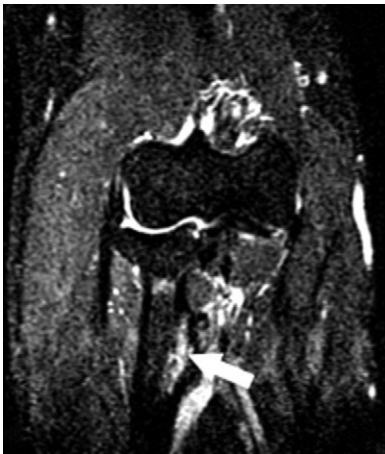**FIGURE 3:** Axial image, Short Tau Inversion Recovery sequence. Partial tear. Peritendinous fluid signal (white arrow).

findings with complete biceps tendon rupture were tendon discontinuity (100%), increased signal intensity in the surrounding soft tissue (75%), and peritendinous fluid signal (74.9%). The most common MRI findings with partial tendon tears were increased intratendinous signal intensity (63.7%), peritendinous fluid signal (61.4%), and increased signal intensity in the surrounding soft tissue (32%) (Table 4, Figs. 1–5).

We recognize that estimating the amount of a partial tear is probably subject to error. Tears that represent a substantial portion of the tendon or, just the opposite, tears that represent only a small percentage of the distal biceps attachment are probably easier to grade and less subject to error. As a consequence, we went back and divided our partial tears into 3 surgical groups: low-grade partial tears representing detachment of 0% to 25% of the tendon; middle-grade partial tears represent-



**FIGURE 4:** Axial image, Short Tau Inversion Recovery sequence. Complete tear. Increased signal intensity in biceps brachii muscle and surrounding soft tissue (white arrow).



**FIGURE 5:** Coronal image, Short Tau Inversion Recovery sequence. Partial tear. Increased signal at radial tuberosity, indicating bone edema (white arrow).

ing detachment of 26% to 75% of the distal biceps tendon, and high-grade partial tears representing detachment of 76% to 99% of the distal biceps tendon. Even when we looked at our partial tears with a broad middle ground representing anywhere from 26% to 75% detachment, the radiologists still read some as intact and some as completely torn (Tables 5, 6).

When the study was complete, we told the radiologists the surgical findings and allowed them to review the films with known distal biceps tendon tears and modify their interpretations. The low-grade partial tears that were read as having no tears all had some degree of tendinosis. Two of the high-grade partial tears that were read as having no tears were in the same patient. In retrospect, this patient's scan should not have been accepted. The MRI scans had moderate motion artifact,

poor spatial resolution, and an incomplete axial T2 study that did not go far enough down to the radial tuberosity. Despite these shortcomings, 1 of the radiologists re-read the study as showing a thin tendon consistent with a partial tear. A third patient with a high-grade tear that was read by 1 of the radiologists as having no tear had a fair amount of tendon still attached to the tuberosity, which gave the false appearance of an intact tendon.

## DISCUSSION

Several studies have evaluated distal biceps tendon tears by MRI. In Falchook et al,<sup>24</sup> 2 radiologists experienced in musculoskeletal imaging retrospectively evaluated the MRI scans of 20 patients with suspected distal biceps injuries. Ten complete and 6 partial tears were diagnosed, but not all cases were surgically confirmed. Common findings on MRI for complete distal biceps rupture included discontinuity of the tendon at its insertion site, a fluid-filled tendon sheath, and increased signal intensity in the biceps muscle belly and surrounding soft tissues. Common findings for partial tears included intratendinous fluid signal, edema in the radial tuberosity, and increased fluid signal intensity in the tendon sheath. In a similar retrospective study, Fitzgerald et al<sup>25</sup> evaluated the MRI scans of 21 patients suspected of having distal biceps tendon injuries. Of those patients, 12 were diagnosed with complete tears, and 4 with partial tears. Again, surgical confirmation was not obtained in all cases. MRI findings for complete and partial biceps tendon tears were similar to those found in the Falchook et al study and are consistent with the findings in our study (Table 4).

O'Driscoll et al compared the accuracy of both MRI and surgical findings when reporting on the accuracy of a specific physical examination maneuver (the hook test). The study evaluated 12 partial tears and 33 complete tears in patients who were eventually treated surgically. A total of 11 of 12 partial tears and 11 of 13 complete tears were identified correctly on MRI. The accuracy of MRI in O'Driscoll's study was 85% in detecting complete tears and 92% in detecting partial tears.<sup>27</sup> In our study, the overall accuracy of MRI in detecting distal biceps tendon ruptures was 92.4%. The accuracy in detecting complete tears was 100%, whereas the accuracy for partial tears was notably lower, at 59.1%. Unlike the work by O'Driscoll et al, our study also looked at the degree of the partial tear (low-grade or high-grade).

Distal biceps tendon ruptures, like other tendon ruptures, represent a spectrum of injury ranging from a complete tear to one that is still attached by varying

**TABLE 5. Detailed Comparison of Radiologist #1's MRI Interpretation and Surgical Findings**

Radiologist's Interpretation	Surgical Findings				
	No Tear	Low-Grade Partial	Mid-Grade Partial	High-Grade Partial	Complete Tear
No tear	<b>10</b>		1	2	
Low-grade partial		<b>1</b>	5	3	
High-grade partial			2	<b>1</b>	
Complete tear			1	6	<b>24</b>

Data reflect a third middle group of partial tears broken out from the original high- and low-grade partial tears confirmed at surgery. Bolded values represent agreement of radiologist's interpretation with surgical findings.

**TABLE 6. Comparison of Radiologist #2's MRI Interpretation and Surgical Findings**

Radiologist's Interpretation	Surgical Findings				
	No Tear	Low-Grade Partial	Mid-Grade Partial	High-Grade Partial	Complete Tear
No tear	<b>10</b>	1	1	2	
Low-grade partial			6	4	
High-grade partial			1	<b>3</b>	
Complete tear			1	3	<b>24</b>

Data reflect a third middle group of partial tears broken out from the original high- and low-grade partial tears confirmed at surgery. Bolded values represent agreement of radiologist's interpretation with surgical findings.

amounts of tissue. Complete ruptures are generally a dramatic event and are usually recognized by both the patient and the physician. Partial tears are not always as dramatic, but generally present as anterior elbow pain. When the diagnosis of distal biceps tendon rupture is in question, MRI of the elbow is often performed. This study highlights the problems associated with determining treatment based on the clinical evaluation and the MRI interpretation. How is one to diagnose a partial distal biceps tendon tear accurately if the MRI scan is not always accurately interpreted and a pseudotendon or tethering of the distal biceps tendon can make a complete distal biceps tendon rupture appear to be only partially ruptured?

Although surgical confirmation has an obvious advantage, it can introduce a selection bias. Partial tears that require surgery may be more symptomatic, more significant, and, theoretically, more obvious on MRI. For this reason, we analyzed the percentage of the tendon detached from the tuberosity in our partial tears. We characterized 6 partial tears as low-grade ( $\leq 50\%$  detached), and 16 as high-grade ( $> 50\%$  detached).

When low-grade tears were misdiagnosed on MRI (1 of 6 by radiologist #1 and 2 of 6 by radiologist #2), all were identified as having some degree of tendinopathy.

This suggests a difficulty in distinguishing tendinosis from low-grade partial distal biceps tears. A study by Williams et al<sup>26</sup> highlighted this point. In that study, 2 musculoskeletal radiologists retrospectively evaluated 20 elbow MRIs of patients suspected of having partial distal biceps rupture. The most common findings included increased signal intensity in the tendon, bicipitoradial bursitis, and increased bone marrow signal edema at the tendon insertion site. Increased intratendinous signal intensity could be interpreted as a partial tear, but Williams et al. concluded that it could also be the result of tendinosis. Although we included an asymptomatic control group in our study, no cases of confirmed tendinosis were knowingly included.

Our study did not compare retracted distal biceps tendon tears with nonretracted distal biceps tendon tears, but we suspect that retracted tears are more obvious than nonretracted tears on MRI, and consequently the amount of retraction could affect the degree of accuracy in diagnosing complete tears on MRI. We used no standardized method to quantify the degree of tendon retraction in this study, but all surgical notes commented on the presence or absence of retraction. A total of 75% of complete tears were identified as having some degree of retraction.

The degree of accuracy in diagnosing distal biceps tendon ruptures on MRI could also theoretically be affected by the chronicity of the tear. It is possible that chronic tears are more difficult to read on MRI than acute tears, but this was not demonstrated in our results. Of the 10 partial tears that radiologist #1 read as either intact or completely torn, 7 were defined as acute. Of the 8 partial tears that radiologist #2 read as either intact or completely torn, 5 were defined as acute.

The advantage of this study is that the radiologists were not only blinded to the presence of either partial and complete tears, but were also given films from asymptomatic adults. This reduced the bias that would be introduced if the radiologists suspected that all the films demonstrated a distal biceps tendon tear.

In summary, MRI may not be necessary in confirming the diagnosis in all cases of complete distal biceps ruptures. When the diagnosis is in question, MRI of the elbow can be a useful tool to aid in the diagnosis. Although MRI is sensitive in diagnosing complete tears, it is substantially less sensitive in diagnosing partial tears. In our study, high-grade partial tears were more frequently misread than low-grade partial tears. The difference may be based on the degree of retraction. Our study also suggests that there may be a difficulty differentiating tendinosis from low-grade partial tears, and high-grade partial tears from nonretracted complete tears. As with any condition, the diagnosis should not rely on imaging studies alone but should attempt to integrate the history and clinical findings.

## REFERENCES

1. Agins HJ, Chess JL, Hoekstra DV, Teitge RA. Rupture of the distal insertion of the biceps brachii tendon. *Clin Orthop Relat Res* 1988; 234:34–38.
2. Baker BE, Bierwagen D. Rupture of the distal tendon of the biceps brachii: operative versus non-operative treatment. *J Bone Joint Surg* 1985;67A:414–417.
3. Bourne MH, Morrey BF. Partial rupture of the distal biceps tendon. *Clin Orthop Relat Res* 1991;271:143–148.
4. Carroll R, Hamilton LR. Rupture of biceps brachii: a conservative method of treatment. *J Bone Joint Surg* 1967;49A:1016.
5. D'Alessandro DF, Shields CL Jr, Tibone JE, Chandler RW. Repair of distal biceps tendon ruptures in athletes. *Am J Sports Med* 1993;21:114–119.
6. Dellaero DT, Mallon WJ. Surgical treatment of partial biceps tendon ruptures at the elbow. *J Shoulder Elbow Surg* 2006;15:215–217.
7. Dobbie R. Avulsion of the lower biceps brachii tendon: analysis of fifty-one unreported cases. *Am J Surg* 1941;51:662–683.
8. Durr HR, Stabler A, Pfahler M, Matzko M, Refior HJ. Partial rupture of the distal biceps tendon. *Clin Orthop Relat Res* 2000;374:195–200.
9. Friedmann AE. Rupture of the distal biceps brachii tendon: report on 13 cases. *JAMA* 1963;184:60–63.
10. Kron SD, Satinsky VP. Avulsion of the distal biceps brachii tendon. *Am J Surg* 1954;88:657–659.
11. Lee HG. Traumatic avulsion of tendon of insertion of biceps brachii. *Am J Surg* 1951;82:290–292.
12. Leighton MM, Bush-Joseph CA, Bach BR Jr. Distal biceps brachii repair: results in dominant and nondominant extremities. *Clin Orthop Relat Res* 1995;317:114–121.
13. Lintner S, Fischer T. Repair of the distal biceps tendon using suture anchors and an anterior approach. *Clin Orthop Relat Res* 1996;322: 116–119.
14. Louis DS, Hankin FM, Eckenrode JF, Smith PA, Wojtys EM. Distal biceps brachii tendon avulsion: a simplified method of operative repair. *Am J Sports Med* 1986;14:234–236.
15. Ramsey ML. Distal biceps tendon injuries: diagnosis and management. *J Am Acad Orthop Surg* 1999;7:199–207.
16. Rokito AS, McLaughlin JA, Gallagher MA, Zuckerman JD. Partial rupture of the distal biceps tendon. *J Shoulder Elbow Surg* 1996;5: 73–75.
17. Vardakas DG, Musgrave DS, Varitimidis SE, Goebel F, Sotereanos DG. Partial rupture of the distal biceps tendon. *J Shoulder Elbow Surg* 2001;10:377–379.
18. Karanjia ND, Stiles PJ. Cubital bursitis. *J Bone Joint Surg* 1988; 70B:832–833.
19. Aldridge JW, Bruno RJ, Strauch RJ, Rosenwasser MP. Management of acute and chronic biceps tendon rupture. *Hand Clin* 2000;16:497–503.
20. Hang DW, Bach BR Jr, Bojchuk J. Repair of chronic distal biceps brachii tendon rupture using free autogenous semitendinosus tendon. *Clin Orthop Relat Res* 1996;323:188–191.
21. Levy HJ, Mashoof AA, Morgan D. Repair of chronic ruptures of the distal biceps tendon using flexor carpi radialis tendon graft. *Am J Sports Med* 2000;28:538–540.
22. Morrey BF, Askew LJ, An KN, Dobyns JH. Rupture of the distal tendon of the biceps brachii: a biomechanical study. *J Bone Joint Surg* 1985;67A:418–421.
23. Sanchez-Sotelo J, Morrey BF, Adams RA, O'Driscoll SW. Reconstruction of chronic ruptures of the distal biceps tendon with use of an Achilles tendon allograft. *J Bone Joint Surg* 2002;84A:999–1005.
24. Falchhook FS, Zlatkin MB, Erbacher GE, Moulton JS, Bisset GS, Murphy BJ. Rupture of the distal biceps tendon: evaluation with MR imaging. *Radiology* 1994;190:659–663.
25. Fitzgerald SW, Curry DR, Erickson SJ, Quinn SF, Friedman H. Distal biceps tendon injury: MR imaging diagnosis. *Radiology* 1994; 191:203–206.
26. Williams BD, Schweitzer ME, Weishaupt D, Lerman J, Rubenstein DL, Miller LS, et al. Partial tears of the distal biceps tendon: MR appearance and associated clinical findings. *Skeletal Radiol* 2001; 30:560–564.
27. O'Driscoll SW, Goncalves LB, Dietz P. The hook test for distal biceps tendon avulsion. *Am J Sports Med* 2007;35:1865–1869.
28. Giuffre BM, Moss MJ. Optimal positioning for MRI of the distal biceps brachii tendon: flexed abducted supinated view. *AJR Am J Roentgenol* 2004;182:944–946.